

# Myelin Oligodendrocyte Glycoprotein Antibody-Related Disorders in Children: Association with Optic Neuritis and Gender Differences

**K. Donielaitė-Anisė\***

**J. Grikinienė\*\***

**R. Samaitienė-Aleknienė\*\***

\*Faculty of Medicine,  
Vilnius University

\*\*Vilnius University,  
Pediatrics Centre

**Summary.** *Background and aim.* Despite the increasing clinical data on anti-myelin oligodendrocyte glycoprotein (anti-MOG)-associated inflammatory demyelinating diseases, there are many unanswered questions. This article aims to elucidate the peculiarities of clinical presentation, association with optic neuritis (ON), relapsing course, investigations, treatment, and gender differences in pediatric anti-MOG-related disorders.

*Methods.* The study involved 51 patients: 46 patients described in publications and 5 patients treated in Vilnius University Hospital Santaros klinikos Pediatrics Centre between 2017 and 2020.

*Result.* Acute disseminated encephalomyelitis (ADEM) was the most common (61%) clinical syndrome as the first presentation in anti-MOG-associated inflammatory demyelinating diseases in children. ON was present in 23.5% of patients at the beginning of the disease. 49% of children had relapses. ON was present in 49% of patients during the course of the relapsing anti-MOG spectrum disease. There was a statistically significant difference in relapse rate between the patients with and without ON during the course of illness – relapses occurred in 72% of patients with ON and 27% of patients without ON. We found a statistically significant gender difference – girls were more likely to relapse than boys, regardless of the presence of ON. 76% of patients reached full recovery during the follow-up period.

*Conclusions.* For the first time, the disease usually presents as acute disseminating encephalomyelitis. About half of children with myelin-oligodendrocyte glycoprotein spectrum disease experience recurrence of the disease and ON. Girls are significantly more likely to relapse than boys. Children with ON have a higher risk of the disease recurrence.

**Keywords:** myelin-oligodendrocyte glycoprotein, optic neuritis, acute disseminated encephalomyelitis, children, gender differences.

## INTRODUCTION

Myelin-oligodendrocyte glycoprotein (MOG) is expressed in the outermost lamellae of myelin within the central nervous system (CNS). MOG antibodies (Abs) appear in around one-third of children diagnosed with acute demyelinating syndrome (ADS). MOG-Abs related disorders have several clinical presentations, such as acute disseminated encephalomyelitis (ADEM), transverse myeli-

tis, optic neuritis (ON), and multiphasic disseminated encephalomyelitis (MDEM). MOG-Abs are rarely detected in children diagnosed with multiple sclerosis. MOG-Abs-related disorders tend to recur, especially when MOG-abs titers are high, although the presence of MOG-Abs was initially thought to predict better outcome [1–3]. MOG-Abs positive patients experience relapses more often in the optic nerve or spinal cord [4, 5]. However, some data show the opposite, that the initial MOG antibody titers do not help predict relapses, and in fact, monophasic diseases like ADEM usually have higher titers than relapsing disease [2, 6]. In children, MOG-Abs-related disorder, in most cases, is clinically manifested as ADEM, while optic neuritis is more common in adults [7].

### Address:

Kamilė Donielaitė-Anisė  
Santariškių St. 4, LT 08406 Vilnius, Lithuania  
E-mail: kamile.donielaite@mf.vu.lt

© Neurologijos seminarai, 2021. Open Access. This article is distributed under the terms of the Creative Commons Attribution 4.0 International License CC-BY 4.0 (<http://creativecommons.org/licenses/by/4.0/>), which permits unrestricted use, distribution, and reproduction in any medium, provided you give appropriate credit to the original author(s) and the source, provide a link to the Creative Commons license, and indicate if changes were made.

Diagnosis of MOG-Abs-related disorders is based on anamnesis, clinical presentation, and laboratory and radiological findings. ADEM causes inflammation of the brain and spinal cord. Clinical findings include multifocal neurologic symptoms and encephalopathy. Usually, ADEM presents as a monophasic disorder, so exacerbation, which occurs within three months from the first attack, is considered as a part of the same episode. If two attacks occur three months apart, the term multiphasic disseminated encephalomyelitis is used [8]. Patients who do not meet all ADEM criteria are diagnosed with an ADEM-like disorder. Optic neuritis is an inflammation of the optic nerve. This can result in a sudden unilateral or bilateral loss of visual acuity, painful eye movements, visual field deficits, or impaired colour perception [9, 10]. Myelitis damages the spinal cord and causes symptoms such as paralysis of the legs or arms, sensory deficits, and dysfunction of bowel and bladder control. The appearance of a new clinical presentation or new radiological findings three months after the previous attack is considered a relapse [8].

No gender differences of MOG-Abs associated disease were observed in previous pediatric studies [11], while gender differences with a higher female predisposition were found in adult studies [7, 12, 13].

Despite the increasing clinical data on anti-MOG-related disorders, there are many unanswered questions. The purpose of this article is to analyze MOG-related pediatric single case publications (which are usually outside the scope of aggregated data analysis), publications of retrospective analysis of patient groups, and our hospital cases. Therefore, we carried out a study of clinical presentation peculiarities of myelin oligodendrocyte glycoprotein antibody-related disorders in children, their association with ON, the course of relapsing disease, investigations, treatment, and gender differences.

## MATERIALS AND METHODS

We analyzed data of children diagnosed with anti-MOG-associated inflammatory demyelinating diseases described in single case reports, retrospective analyses of patient groups published in the PubMed database from December 2009 to March 2020, and included five patients that were treated in Vilnius University Hospital Santaros klinikos Pediatrics Centre from 2017 to 2020. The search keyword was anti myelin oligodendrocyte glycoprotein.

The initial search resulted in 864 articles. After we excluded articles older than ten years, duplicates, articles of adult patients, non-English language studies, animal and laboratory studies, we were left with 242 articles. We closely reviewed the remaining articles to ensure they meet our inclusion criteria. The inclusion criteria were: children diagnosed with ADEM, MDEM, ON, myelitis, and their combinations, with positive serum anti-MOG test results, and studies in which we were able to obtain the following data: demographic features (age and gender), clinical, laboratory and radiological findings, and treatment. We ex-

cluded articles that did not meet our inclusion criteria or from which we could not extract the information we needed. Eighteen articles met the inclusion criteria, including 46 patients with pediatric anti-MOG spectrum disease. Sixteen of the 18 articles were case reports (14 single case reports, 1 two-case report, 1 three-case report) [1, 14–28], and the remaining two articles were retrospective analyses of patient groups (19 patients and 8 patients) [29, 30]. We added five patients diagnosed with anti-MOG spectrum disease treated in our hospital. Ethics: The study has been approved by the Vilnius Regional Biomedical Ethics Committee (No. 158200-15-797-309).

We divided all patients into two groups: ON (+) and ON (-) groups according to the presence of optic neuritis during the course of the disease. We analyzed demographic and clinical data including initial diagnosis (diagnosis at first attack), final diagnosis (summed clinical diagnoses of all episodes), symptoms, laboratory and radiological findings, and treatment of these patients.

Data comparison between the groups was performed using 2-tailed t-test and Chi-Square test for discrete numeric variables. We used The Mantel-Haenszel chi-squared test to estimate the risk of relapse between the groups taking gender into account. A value of  $p < 0.05$  was considered significant. Analyses were performed using R version 3.3.2.

## RESULTS

### Materials

The study involved 51 patients: 46 patients described in publications and 5 patients treated in Vilnius University Hospital Santaros klinikos Pediatrics Centre between January 2017 and March 2020. Four of 5 patients treated in our hospital were boys and 1 was a girl, with the mean age at disease onset 5.2 years (2 to 13 years). The final diagnosis was ADEM in 2 patients, MDEM in the other 2, and the remaining one was diagnosed with myelitis.

### Clinical and demographic data

Clinical and demographic data, including initial diagnosis, final diagnosis, patients with relapses, gender, and age at onset of patients with anti-MOG spectrum disease are presented in Table 1.

The median age at onset was seven years (mean  $7.5 \pm 4.0$  years, range 1.5–16.5 years). 28/51 patients (55%) were girls (Table 2).

Initial diagnoses were ADEM ( $n=31$ , 60.8%), ADEM-like ( $n=1$ , 1.9%) (this patient did not meet all ADEM criteria), ON ( $n=9$ , 17.6%), ADEM+ON ( $n=2$ , 3.9%), myelitis ( $n=5$ , 9.8%), myelitis+ON ( $n=1$ , 1.9%), MS ( $n=2$ , 3.9%). Optic neuritis presented in 12 patients (23.5%) at the time of the first attack, half (50%) of them had a relapse.

Final diagnoses were ADEM ( $n=15$ , 29.4%), MDEM ( $n=6$ , 11.8%), ON ( $n=6$ , 11.8%), ADEM+ON ( $n=12$ ,

Table 1. Clinical and demographic data of patients with anti-MOG spectrum disease

Group	Final diagnosis	Initial diagnosis	Patients with relapses	Gender m:f	Age at onset (years)
ON (-) n=26	ADEM n=15	ADEM n=15	0/15 (0%)	11:4	2-15
	MDEM n=6	ADEM n=5, MS n=1	6/6 (100%)	1:5	4-14.5
	Myelitis n=5	Myelitis n=5	1/5 (20%)	3:2	5.5-13
ON (+) n=25	ON n=6	ON n=6	2/6 (33%)	3:3	6-13
	ADEM+ON n=12	ADEM n=9, ADEM+ON n=2, ON n=1	11/12 (92%)	3:9	1.5-12
	MDEM+ON n=2	ADEM n=2	2/2 (100%)	0:2	4.5-8
	Myelitis+ON n=3	Myelitis+ON n=1, ON n=1, MS n=1	2/3 (67%)	1:2	9-16.5
	ADEM like +ON n=2	ADEM like n=1, ON=1	1/2 (50%)	1:1	7

m - male, f - female, ADEM - acute disseminated encephalomyelitis, ON - optic neuritis, MDEM - multiphasic disseminated encephalomyelitis, MS - multiple sclerosis, ADEM like - these patients did not meet all ADEM criteria.

Table 2. Data on age and gender

	Females (n=28, 54.9%)	Males (n=23, 45.1%)
Average age at the beginning of the disease	7.75 years	7.2 years
Average age of patients who had relapses	7.38 years	8.2 years

23.5%), MDEM+ON (n=2, 3.9%), myelitis (n=5, 9.8%), myelitis+ON (n=3, 5.9%), ADEM-like+ON (n=2, 3.9%). Optic neuritis presented in 25 patients (49.0%) during the course of the disease. Initial and final diagnoses are shown in Figure.

According to the final diagnosis, the patients were assigned to the ON (-) group (n=26) or ON (+) group (n=25) (Table 1, Table 3).

**History of previous illnesses or vaccinations**

Seven patients (13.7%) had a history of infection (upper respiratory tract, varicella, influenza), three patients (5.8%) were vaccinated (influenza, MMR, Japanese encephalitis vaccines) in 4 weeks period before the first symptoms, one patient (1.9%) had a history of autoimmune thyroiditis, one patient (1.9%) had a family history of autoimmune diseases - MS, and one patient (1.9%) had a developmental disorder.

**Clinical symptoms and disease course**

Data about clinical symptoms were available from 31 patients. Most common symptoms at the first attack were encephalopathy n=17 (54.8%), vision disturbances n=12 (38.7%), gait disturbances n=11 (35.5%), fever n=10 (32.3%), seizures n=8 (25.8%), and motor dysfunction n=8 (25.8%). Other symptoms were headache n=7 (22.6%), bowels or bladder dysfunction n=5 (16.1%), vomiting n=5 (16.1%), cranial nerves dysfunction n=4 (12.9%), speech disorders n=4 (12.9%), pain n=4 (12.9%), and dyskinesia n=1 (3.2%).

At least one relapse (range 1-9) was reported in 25/51 (49.0%) patients. 7/26 patients (27%) in ON (-) group and 18/25 (72%) patients in ON (+) group had at

least one relapse (Table 2). There was statistical significance between the groups (p=0.003). The risk for females to relapse was significantly higher than the risk for males in both ON (-) and ON (+) groups (p=0.02).

**Cerebrospinal fluid (CSF) analysis**

33/51 (64.7%) patients had at least one lumbar puncture performed at disease onset or relapse. 10/33 (30.3%) had a

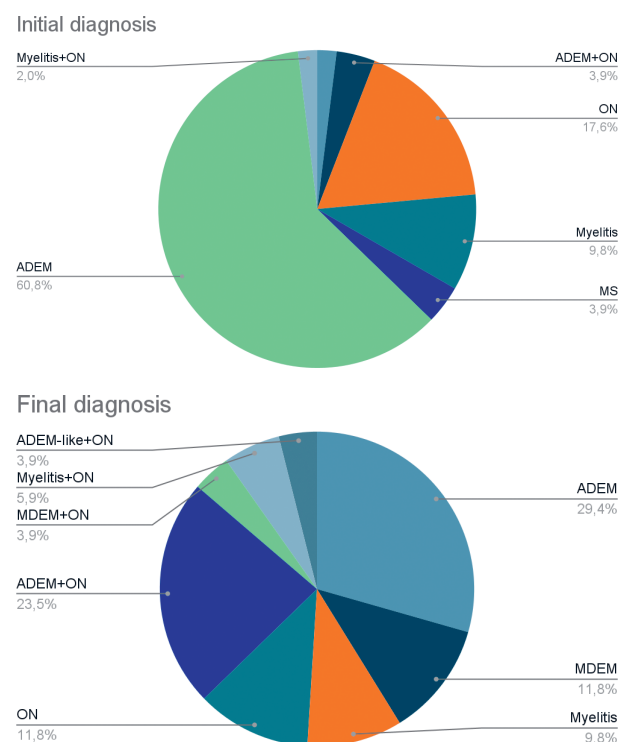


Fig. Initial and final diagnoses of patients with anti-MOG spectrum disease

Table 3. Clinical data of patients of ON (-) and ON (+) groups

	Group ON (-)	Group ON (+)
Patients (n, %)	26/51 (51%)	25/51 (49%)
Age at onset (years) mean±SD	7.1±4.1 (range 2–15)	7.9±3.9 (range 1.5–16.5)
Gender m:f	15:11	8:17
Relapses (n, %)	7/26 (27%)*	18/25 (72%)*
Relapses (gender m:f)	1:6*	6:12*
Changes in brain MRI/performed MRI (n, %)	22/26 (85%)	21/24 (88%)
Changes in spine MRI/performed MRI (n, %)	7/18 (39%)	5/16 (31%)
Residual deficit (n, %)	8/26 (31%)	4/25 (16%)

m - male, f - female, MRI - magnetic resonance images, \* - statistically significant difference between groups (p<0.05).

CSF pleocytosis and 10/33 (30.3%) had an elevated CSF protein. The glucose level in all 33 patients was normal. IgG index was tested in 23/51 (45.1%) patients, and in 3/23 (13%) patients it was found to be elevated. All three of these patients were from the ON (-) group. Oligoclonal bands were found in 4/23 (17.4%) patients, half of them were from the ON (-) group. Myelin basic protein was elevated in 2/5 (40%) patients.

### Neuroimaging

Brain magnetic resonance images (MRI) were performed in 50/51 (98%) patients, spine MRI in 34/51 (67%) patients (Table 2). Demyelinating brain MRI changes were found in 43/50 (86%) patients. Demyelinating spine MRI changes were found in 12/34 (35%) patients.

Control MRI was performed in 23/51 (45%) patients. A complete or nearly complete radiographic resolution was found in 16/23 (70%) patients and incomplete in 7/23 patients (30%). Five of these 7 patients were from the ON (-) group. Control MRI was usually performed 3 to 6 months after the attack.

### Anti-MOG antibodies

Serum anti-MOG test results were positive in all patients. Anti-MOG antibodies were re-tested in 10/51 (19.6%) patients. They remained positive in 6/10 (60%) patients, 3 in the ON (+) group, and 3 in the ON (-) group. Only one patient whose anti-MOG antibodies remained positive had no relapse.

### Infectious agents and immunologic markers

Various infectious agents were tested in 12/51 (23.5%) patients, and almost all were negative. One patient had a positive CFS polymerase chain reaction for human herpes virus 6. Immunologic markers, such as antinuclear antibodies, anti-double-stranded DNA, peri-nuclear and cytoplasmic anti-neutrophil cytoplasmic antibodies, thyroglobulin, thyroperoxidase, etc., were tested in 4/51 (7.8%) patients, and one patient's antinuclear antibody test was positive.

### Treatment

At the first attack, 47/51 (92%) patients were treated with glucocorticoids (most often intravenous pulse methylprednisolone) and 2/51 (4%) with intravenous immune globulin (IVIG). 7/47 (15%) patients who received glucocorticoids also received IVIG. 1/47 (2.1%) patients were treated with rituximab. Plasmapheresis was performed for 2/47 (4.3%) patients. During maintenance treatment, oral prednisolone taper was used for 28/51 (54.9%) patients - 13/26 (50%) from the ON (-) group and 15/25 (60%) from the ON (+) group.

Among children with relapses, glucocorticoids were used in 12 patients, IVIG in 6, and plasmapheresis in 3. Additional long-term therapy with azathioprine, mycophenolate mofetil, fingolimod, rituximab, tocilizumab, or interferon beta was used in 16/51 (31.4%) patients, 12 of which (75%) were from the ON (+) group.

### Outcomes and follow-up

39/51 (76%) patients reached full recovery. 8/26 (31%) ON (-) group patients and 4/25 (16%) ON (+) group patients had residual deficits, such as visual impairment n=3, motor deficit n=5, seizures n=1, cognitive impairment n=2, speech disorder n=1, sensory deficit n=1, and bladder dysfunction n=1 (Table 2).

Minimum follow-up duration was 3 months, maximum 252 months (21 years), and mean 45.5 months (data were available from 42 patients). Average duration of follow-up was 43.9 months in the ON (-) group and 66.6 months in the ON (+) group.

### DISCUSSION

In this article, we focused on patient reports and retrospective analyses from the PubMed database, as well as data from our hospital patients with pediatric onset of anti-MOG antibody disorders. As the course of the disease can be very diverse, it is still unclear how to predict the severity and recurrence of the disease. Pediatric Anti-MOG relapsing diseases appear to represent age-dependent pheno-

types: brain involvement only is more common in younger children, and ON and NMO spectrum disorders in older children (mean age 4.1 and 8.9 years) [6, 31–33]. There were no differences in age of onset between the groups in our study.

Approximately 37% of ADEM patients and 57–74% of pediatric ADEM patients are associated with various previous infections, suggesting that it is immunologically mediated [34–36]. We found a history of previous infection in a minority of patients (13.7%) and a history of vaccination in 5.8% of patients. No acute infectious agents were found, except for one case that tested positive for herpesvirus 6 in our study.

Predominant anti-MOG syndromes differ in children and adults. Anti-MOG disorders in children usually are seen clinically as ADEM phenotype, whereas bilateral optic neuritis usually predominates in adults. In a study of 59 patients with relapsing anti-MOG syndromes (33 children and 26 adults), the main presentations in the pediatric group were ADEM (36%), bilateral optic neuritis (24%), and unilateral optic neuritis (15%) [7]. Initial diagnoses were ADEM in 60.8% of cases in our study; 12 patients (23.5%) had optic neuritis at the time of the first attack.

The symptoms were very diverse and varied in each analyzed case. Symptoms during exacerbations were often different from previous symptoms in the patients we analyzed. The most common symptoms were encephalopathy, vision disturbances, gait disturbances, fever, seizures, and motor dysfunction. Similar symptoms were found in a multicenter observational pediatric study of Thais Armangue et al. [37].

Abnormalities were found in 73.3% of pediatric MOG Ab patients on brain MRI and in 33.3% of patients on spinal MRI [38]. Approximately 45% of patients had abnormal brain MRI scans at the onset of the disease [39]. We found nearly similar results in the patients we analyzed. We did not find substantial differences in MRI data between the groups. Control MRI was usually performed 3 to 6 months after the attack, 69.6% of MRI showed complete or nearly complete radiographic resolution.

In our study, more than half of the patients had at least one lumbar puncture performed at the disease onset or during relapses. There were no specific changes in CSF. Almost one third of the patients had pleocytosis and elevated protein level, IgG index and oligoclonal bands were elevated in a minority of patients. In a study of 8 MDEM MOG positive children, 87.5% showed CSF pleocytosis and oligoclonal bands were elevated in 12.5% of patients [31].

Relapse ratio data in pediatric MOG Ab-positive patients are contradictory. The duration of follow-up reported in the studies varied significantly. A monophasic disease course was found in 61–87% of patients [5, 6, 11]. The relapse ratio was 28% in 116 patients after a median follow-up of 42 months [37]. In a study of patients with ADEM, 54% of children experienced a relapse over time (followed up for a median of 6 years (range 1–16 years) [40].

It seems that relapsing MOG antibody-associated demyelination is strongly associated with ON in children. Relapsing NMOSD was the main relapsing clinical syndrome in the pediatric cohort (21% and 46%) followed by ON (18%) and ADEM-ON (12%) [4, 5]. Relapses in anti-MOG antibody-positive participants were more commonly restricted to the optic nerve or spinal cord [5]. In a study of 31 pediatric patients (median follow-up 80 months), the relapsing disease occurred in 74%, the most common attack among patients was ON (80.6%) [4]. Our study demonstrated that the relapsing course of the disease was strongly associated with ON in children. Optic neuritis was present in nearly half (49.0%) of the patients during the course of relapsing anti-MOG spectrum disease, while it was present in 23.5% of patients during the first attack. Our study revealed a significant difference in relapse ratio between the groups: relapses occurred in 72% of patients with ON and in 27% of patients without ON.

No gender differences of MOG Ab associated disease were observed in previous pediatric studies [11]. Some gender differences with a higher female predisposition were found in adult studies. Jarius et al. found a gender ratio of 1:2.8 (m:f) in pediatric and adult patients with NMOSD [12]. Women accounted for 57% of the patients analyzed in the UK adult study of MOG-antibody diseases [13]. We found gender differences when examining relapses in the ON (+) and ON (-) patient groups: girls were significantly more likely to relapse than boys in both groups. It is known that girls are more likely to have chronic autoimmune diseases that are observed after puberty, but there was no age difference between our study groups.

Persistent MOG-IgG positivity during follow-up examination indicated a risk of subsequent relapse [4], but not in all studies. According to a study of Waters P et al. [5], of 16 children who were positive for anti-MOG antibodies at presentation and experienced clinical relapses, 9 (56%) were persistently seropositive (representing 28% of all persistently seropositive participants). We found that all patients, except one whose Anti-MOG Ab remained positive, had at least one relapse, equally in both groups.

To date, there are no evidence-based guidelines for the acute treatment of children with MOG-Ab. At the beginning of the treatment, the focus is usually on the removal of systemic antibodies and immunosuppression. The explanations for the heterogeneity in treatment response may be that MOG-Ab-specific damage is induced by multiple pathogenic mechanisms [41]. A study by Hacoen et al showed the effectiveness of azathioprine, mycophenolate mofetil, rituximab, and especially intravenous immunoglobulins, but not multiple sclerosis disease-modifying drugs, in managing relapses in children [33]. We found that most patients received glucocorticoids and a minority received IVIG, glucocorticoids together with IVIG/plasmapheresis, or rituximab during their first attack as first-line treatment. Oral prednisolone taper was used in

more than half of the patients. Treatment during relapses was very diverse, with first-line treatment followed by secondary prevention treatment in two thirds of patients in the ON (+) group. Residual deficits did not differ between the groups in our study.

This study has some limitations. First, this is not a registry-based study and we could not assess the incidence and prevalence of MOG antibody-associated ON and relapses. Second, publications on single cases usually include distinct cases, therefore, our study presents a diverse group of patients, with almost half of the patients having non typical disease courses. The duration of follow-up in the ON (+) group was longer, so there may be a possibility that patients in the ON (-) group may experience a relapse or optic neuritis in the future.

## CONCLUSIONS

1. The course of pediatric MOG Ab associated disease can be very diverse, and symptoms during exacerbations often differ from previous symptoms.
2. ADEM was the most common clinical syndrome as the first presentation of anti-MOG spectrum disease in children (61%).
3. Nearly half (49%) of the children with anti-MOG-associated inflammatory demyelinating diseases had relapses.
4. Optic neuritis was present in nearly half (49%) of patients during the course of the relapsing anti-MOG spectrum disease, while it was present in 23.5% of the patients at the beginning of the disease.
5. The relapsing course of the disease was strongly associated with ON in children: relapses occurred in 72% of patients with ON and in 27% of patients without ON.
6. A statistically significant gender difference was found – girls were more likely to relapse than boys, regardless of the presence of ON.
7. Full recovery was observed in 76% of patients during the follow-up period.

## References

1. Yokoyama K, Hori M, Yoshida A. Anti-myelin oligodendrocyte glycoprotein antibody neuritis optica following anti-NMDA receptor encephalitis. *Pediatr Int* 2016; 58: 953–4. <https://doi.org/10.1111/ped.13053>
2. Hennes E-M, Baumann M, Lechner C, et al. MOG spectrum disorders and role of MOG-antibodies in clinical practice. *Neuropediatrics* 2018; 49(01): 003–011. <https://doi.org/10.1055/s-0037-1604404>
3. Ungureanu A, de Seze J, Ahle G, et al. Myelin oligodendrocyte glycoprotein antibodies in neuromyelitis optica spectrum disorder. *Rev Neurol (Paris)* 2018; 174: 675–9. <https://doi.org/10.1016/j.neuro.2018.01.378>
4. Oliveira LM, Apóstolos-Pereira SL, Pitombeira MS, et al. Persistent MOG-IgG positivity is a predictor of recurrence in MOG-IgG-associated optic neuritis, encephalitis and myeli-

- tis. *Mult Scler* 2019; 25: 1907–14. <https://doi.org/10.1177/1352458518811597>
5. Waters P, Fadda G, Woodhall M, et al. Serial anti-myelin oligodendrocyte glycoprotein antibody analyses and outcomes in children with demyelinating syndromes. *JAMA Neurol* 2020; 77(1): 82–93. <https://doi.org/10.1001/jamaneurol.2019.2940>
6. Hennes E-M, Baumann M, Schanda K, et al. Prognostic relevance of MOG antibodies in children with an acquired demyelinating syndrome. *Neurology* 2017; 89: 900–8. <https://doi.org/10.1212/WNL.0000000000004312>
7. Ramanathan S, Mohammad S, Tantsis E, et al. Clinical course, therapeutic responses and outcomes in relapsing MOG antibody-associated demyelination. *J Neurol Neurosurg Psychiatry* 2018; 89: 127–37. <https://doi.org/10.1136/jnnp-2017-316880>
8. Lee YJ. Acute disseminated encephalomyelitis in children: differential diagnosis from multiple sclerosis on the basis of clinical course. *Korean J Pediatr* 2011; 54: 234–40. <https://doi.org/10.3345/kjp.2011.54.6.234>
9. Pérez-Cambrodí RJ, Gómez-Hurtado Cubillana A, Merino-Suárez ML, et al. Optic neuritis in pediatric population: a review in current tendencies of diagnosis and management. *J Optom* 2014; 7(3): 125–30. <https://doi.org/10.1016/j.optom.2013.12.008>
10. Yeh EA, Graves JS, Benson LA, et al. Pediatric optic neuritis. *Neurology* 2016; 2016; 87: S53–8. <https://doi.org/10.1212/WNL.0000000000002822>
11. Hacohen Y, Absoud M, Deiva K, et al. Myelin oligodendrocyte glycoprotein antibodies are associated with a non-MS course in children. *Neurol Neuroimmunol Neuroinflamm* 2015; 2(2): e81. <https://doi.org/10.1212/NXI.0000000000000081>
12. Jarius S, Ruprecht K, Kleiter I, et al. MOG-IgG in NMO and related disorders: a multicenter study of 50 patients. Part 2: Epidemiology, clinical presentation, radiological and laboratory features, treatment responses, and long-term outcome. *J Neuroinflammation* 2016; 13: 280. <https://doi.org/10.1186/s12974-016-0718-0>
13. Jurynczyk M, Messina S, Woodhall MR, et al. Clinical presentation and prognosis in MOG-antibody disease: a UK study. *Brain* 2017; 140: 3128–38. <https://doi.org/10.1093/brain/awx276>
14. Lee AR, El-Dairi MA. Anti-myelin oligodendrocyte glycoprotein optic neuritis or neuroretinitis? *JAMA Ophthalmol* 2018; 136(10): e182928. <https://doi.org/10.1001/jamaophthalmol.2018.2928>
15. Miyauchi A, Watanabe M, Sugie H, et al. Persistent presence of the anti-myelin oligodendrocyte glycoprotein autoantibody in a pediatric case of acute disseminated encephalomyelitis followed by optic neuritis. *Neuropediatrics* 2014; 45: 196–9. <https://doi.org/10.1055/s-0034-1371179>
16. Bellinvia A, Pastò L, Razzolini L, et al. The clinical spectrum of anti-MOG associated acquired demyelinating disorders: three case-reports. *Mult Scler Relat Disord* 2019; 33: 51–4. <https://doi.org/10.1016/j.msard.2019.05.006>
17. Ching BH, Mohamed AR, Khoo TB, et al. Multiphasic disseminated encephalomyelitis followed by optic neuritis in a child with gluten sensitivity. *Mult Scler* 2015; 21: 1209–11. <https://doi.org/10.1177/1352458515593404>
18. Wang C, Narayan R, Greenberg B. Anti-myelin oligodendrocyte glycoprotein antibody associated with gray matter predominant transverse myelitis mimicking acute flaccid myelitis: a presentation of two cases. *Pediatr Neurol* 2018;

- 86: 42–5. <https://doi.org/10.1016/j.pediatrneurol.2018.06.003>
19. Sarigecili E, Cobanogullari MD, Komur M, et al. A rare concurrence: antibodies against myelin oligodendrocyte glycoprotein and N-methyl-D-aspartate receptor in a child. *Mult Scler Relat Disord* 2019; 28: 101–3. <https://doi.org/10.1016/j.msard.2018.12.017>
  20. Tani H, Ishikawa N, Kobayashi Y, et al. Anti-MOG antibody encephalitis mimicking neurological deterioration in a case of Rett syndrome with MECP2 mutation. *Brain Dev* 2018; 40: 943–6. <https://doi.org/10.1016/j.braindev.2018.06.011>
  21. Vieira JP, Sequeira J, Brito MJ. Postinfectious anti-myelin oligodendrocyte glycoprotein antibody positive optic neuritis and myelitis. *J Child Neurol* 2017; 32: 996–9. <https://doi.org/10.1177/0883073817724927>
  22. Gutman JM, Kupersmith M, Galetta S, et al. Anti-myelin oligodendrocyte glycoprotein (MOG) antibodies in patients with optic neuritis and seizures. *J Neurol Sci* 2018; 387: 170–3. <https://doi.org/10.1016/j.jns.2018.01.042>
  23. Lang J, Biebl A, Gruber A, et al. Teaching Case 5-2018: integrated morphological and immunological work-up of neurosurgical specimen allows accurate diagnosis of neuroinflammatory lesions: an example of acute disseminated encephalomyelitis (ADEM) associated with anti-MOG antibodies. *Clin Neuropathol* 2018; 37: 206–8. <https://doi.org/10.5414/NP301136>
  24. Bechtel-Walz W, Walz G, Neumann-Haefelin E. Long-term therapeutic plasma exchange therapy as effective approach to refractory primary acquired pregnancy-related thrombocytopenic purpura. *Ther Apher Dial* 2019; 23(1): 99–100. <https://doi.org/10.1111/1744-9987.12748>
  25. Kanamori K, Tsuchida S, Tamura M. Role of plasma exchange in the management of pediatric optic neuritis with antibodies against myelin oligodendrocyte glycoprotein. *Ther Apher Dial* 2019; 23(1): 100–1. <https://doi.org/10.1111/1744-9987.12751>
  26. Azumagawa K, Nomura S, Shigeri Y, et al. Post-vaccination MDEM associated with MOG antibody in a subclinical Chlamydia infected boy. *Brain Dev* 2016; 38: 690–3. <https://doi.org/10.1016/j.braindev.2016.02.004>
  27. Nagashima M, Osaka H, Ikeda T, et al. Rituximab was effective for acute disseminated encephalomyelitis followed by recurrent optic neuritis with anti-myelin oligodendrocyte glycoprotein antibodies. *Brain Dev* 2018; 40: 607–11. <https://doi.org/10.1016/j.braindev.2018.03.011>
  28. Tsuburaya RS, Miki N, Tanaka K, et al. Anti-myelin oligodendrocyte glycoprotein (MOG) antibodies in a Japanese boy with recurrent optic neuritis. *Brain Dev* 2015; 37: 145–8. <https://doi.org/10.1016/j.braindev.2014.02.002>
  29. Konuskan B, Yildirim M, Gocmen R, et al. Retrospective analysis of children with myelin oligodendrocyte glycoprotein antibody-related disorders. *Mult Scler Relat Disord* 2018; 26: P1–7. <https://doi.org/10.1016/j.msard.2018.07.022>
  30. Hino-Fukuyo N, Haginoya K, Nakashima I, et al. Clinical features and long-term outcome of a group of Japanese children with inflammatory central nervous system disorders and seropositivity to myelin-oligodendrocyte glycoprotein antibodies. *Brain Dev* 2015; 37: 849–52. <https://doi.org/10.1016/j.braindev.2015.02.006>
  31. Baumann M, Hennes E-M, Schanda K, et al. Children with multiphasic disseminated encephalomyelitis and antibodies to the myelin oligodendrocyte glycoprotein (MOG): extending the spectrum of MOG antibody positive diseases. *Mult Scler* 2016; 22: 1821–9. <https://doi.org/10.1177/1352458516631038>
  32. Hacoheh Y, Rossor T, Mankad K, et al. ‘Leukodystrophy-like’ phenotype in children with myelin oligodendrocyte glycoprotein antibody-associated disease. *Dev Med Child Neurol* 2018; 60: 417–23. <https://doi.org/10.1111/dmcn.13649>
  33. Hacoheh Y, Wong YY, Lechner C, et al. Disease course and treatment responses in children with relapsing myelin oligodendrocyte glycoprotein antibody-associated disease. *JAMA Neurol* 2018; 75(4): 478–87. <https://doi.org/10.1001/jamaneurol.2017.4601>
  34. Dale RC. Acute disseminated encephalomyelitis, multiphasic disseminated encephalomyelitis and multiple sclerosis in children. *Brain* 2000; 123: 2407–22. <https://doi.org/10.1093/brain/123.12.2407>
  35. Schwarz S, Mohr A, Knauth M, et al. Acute disseminated encephalomyelitis: a follow-up study of 40 adult patients. *Neurology* 2001; 56: 1313–8. <https://doi.org/10.1212/WNL.56.10.1313>
  36. Elhassanien A, Aziz H. Acute demyelinating encephalomyelitis: clinical characteristics and outcome. *J Pediatr Neurosci* 2013; 8(1): 26–30. <https://doi.org/10.4103/1817-1745.111418>
  37. Armangue T, Olivé-Cirera G, Martínez-Hernández E, et al. Associations of paediatric demyelinating and encephalitic syndromes with myelin oligodendrocyte glycoprotein antibodies: a multicentre observational study. *Lancet Neurol* 2020; 19: 234–46. [https://doi.org/10.1016/S1474-4422\(19\)30488-0](https://doi.org/10.1016/S1474-4422(19)30488-0)
  38. Chen L, Chen C, Zhong X, et al. Different features between pediatric-onset and adult-onset patients who are seropositive for MOG-IgG: a multicenter study in South China. *J Neuroimmunol* 2018; 321: 83–91. <https://doi.org/10.1016/j.jneuroim.2018.05.014>
  39. Wynford-Thomas R, Jacob A, Tomassini V. Neurological update: MOG antibody disease. *J Neurol* 2019; 266: 1280–6. <https://doi.org/10.1007/s00415-018-9122-2>
  40. Rossor T, Benetou C, Wright S, et al. Early predictors of epilepsy and subsequent relapse in children with acute disseminated encephalomyelitis. *Mult Scler* 2020; 26: 333–42. <https://doi.org/10.1177/1352458518823486>
  41. Hacoheh Y, Banwell B. Treatment approaches for MOG-antibody-associated demyelination in children. *Curr Treat Options Neurol* 2019; 21: 2. <https://doi.org/10.1007/s11940-019-0541-x>

**K. Donielaitė-Anisė, J. Grikinienė,  
R. Samaitienė-Aleknienė**

#### **AUTOANTIKŪNŲ PRIEŠ MIELINO OLIGODENDROCITŲ GLIKOPROTEINĄ SUKELTŲ LIGŲ YPATUMAI VAIKAMS: RYŠYS SU OPTINIŲ NEURITU IR LYČIŲ SKIRTUMAI**

#### **Santrauka**

*Tikslas.* Nepaisant vis daugėjančių klinikinių duomenų apie uždegimines demielinizuojančias ligas, susijusias su autoantikūnais prieš mielino oligodendrocitų glikoproteiną (MOG spektro ligas), išlieka daug neatsakytų klausimų. Šiuo straipsniu siekiama išsiaiškinti pediatriinių MOG spektro ligų klinikinių simptomų ypatumus, ryšį su optiniu neuritu (ON), recidyvuojančia ligos eiga ir tyrimų, gydymo bei lyčių skirtumus.

*Metodai.* Tyrime analizavome publikacijose rastus 46 pacientų duomenis ir Vilniaus universiteto ligoninėje Santaros klinikos, Pediatrijos centre nuo 2017 iki 2020 m. gydytų 5 pacientų duomenis (iš viso 51 pacientas).

*Rezultatai.* Vaikams MOG spektro liga dažniausiai pirmą kartą manifestuoja kaip ūminis diseminuotas encefalomyelitas (61 % atvejų). ON ligos pradžioje buvo nustatytas 23,5 % pacientų. Liga atsinaujino 49 % vaikų. 49 % pacientų, kuriems MOG spektro liga atsinaujino, buvo diagnozuotas ON. Statistiškai reikšmingai dažniau liga atsinaujindavo tiems pacientams, kuriems buvo diagnozuotas ON, – ligos paūmėjimai nustatyti 72 % vaikų su ON ir 27 % ON nenustatytas. Recidyvuojanti ligos eiga statistiškai reikšmingai yra dažnesnė mergaitėms, nepriklausomai nuo to, ar joms buvo diagnozuotas ON ar ne. Ste-

bėjimo laikotarpiu be liekamųjų reiškinų pasveiko 76 % pacientų.

*Išvados.* Pirmą kartą liga dažniausiai pasireiškia kaip ūminis diseminuojantis encefalomyelitas. Recidyvuojanti eiga ir ON pasireiškia apie pusę vaikų, sergančių MOG spektro ligomis. Recidyvuojanti ligos eiga yra dažnesnė mergaitėms ir dažnesnė vaikams, kuriems pasireiškė ON.

**Raktažodžiai:** mielino oligodendrocitų glikoproteinas, regos nervo uždegimas, ūminis diseminuotas encefalomyelitas, vaikai, lyčių skirtumai.

Gauta:  
2021 08 13

Priimta spaudai:  
2021 09 30